

# MB-102: A NOVEL TRACER AGENT FOR CANINE OCULAR ANGIOGRAPHY



# MediBeacon

## ANGIOGRAPHY

CG Pirie,<sup>1</sup> RB Dorshow,<sup>2</sup> TE Rogers<sup>2</sup>



MICHIGAN STATE UNIVERSITY  
**VETERINARY**  
MEDICAL CENTER

College of Veterinary Medicine, Michigan State University, East Lansing MI (1), MediBeacon Inc. St. Louis, MO (2)

Work supported by NIH Grant Number 1R43EY027207-01

## Purpose

To evaluate effectiveness of new fluorescence tracer agent, MB-102, for conducting ocular angiography in dogs.

## Methods

Ten normal dogs and 10 dogs with retinal degeneration or primary open angle glaucoma were used. Both male and female dogs were used, all > 3 kg. Normal dogs were 2-4 years of age, and diseased canines were <6 years of age.

Each normal dog received both SF (20 mg/kg) and MB-102 (20 mg/kg) with a two-day washout period in between. For the diseased canines, a dose of 40 mg/kg of MB-102 was utilized; all other conditions were identical.

All dogs were routinely anesthetized. Anterior fluorescence angiography was performed on one eye, and posterior on the other. The order of dye administration and eye selection were randomized. Imaging was performed using a full-spectrum camera and camera adaptor system. Two filter combinations were evaluated; a broadband filter set to allow for reduced illumination requirements and improved capturing of dye fluorescence, and a narrowband filter set tailored to match the emission characteristics of each angiographic dye (Figure 1). The angiographic imaging protocol employed was the same, regardless of the angiographic dye and/or filter set employed. Upon completion of bolus dye administration, imaging occurred at a rate of three images per second, for a total of 30 seconds. Thereafter, imaging was performed at 1, 2, 3, 4, 5, 10, 15, 20, 25, and 30 minutes.

Angiographic dyes were compared subjectively, determining their capacity to allow clear visualization of the vasculature, in addition to assessing their degree of dye extravasation. The time to onset of each phase and phase interval for each angiographic dye were recorded and analyzed via a Wilcoxon signed-rank test.

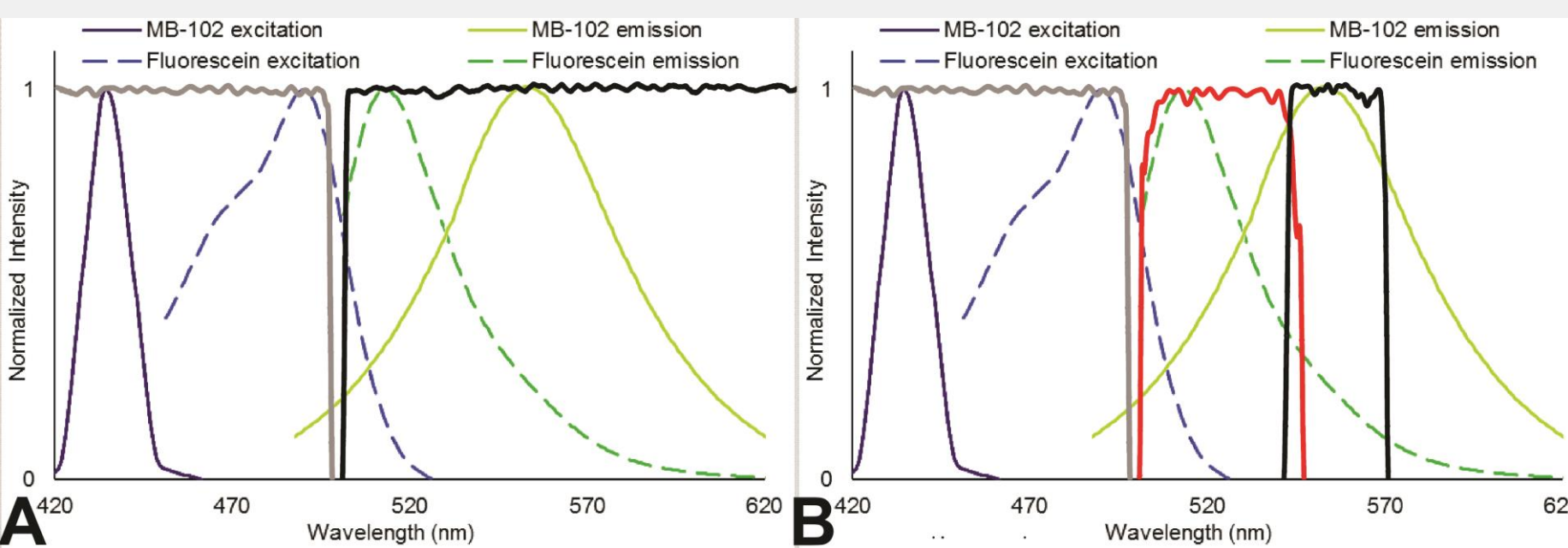


Figure 1

**Figure 1:** The excitation (MB-102; dark blue, SF; blue) and emission (MB-102; green-yellow, SF; green) spectral curves of MB-102 and SF are shown. Broadband filter combination (A) demonstrate excitation (gray) and barrier (black) filter characteristics. Narrowband filter combinations (B) demonstrate the excitation (gray) and barrier filters utilized for SF (red) and MB-102 (black).

**Figure 2:** Representative anterior segment sodium fluorescein (A) and MB-102 angiography (B) images obtained at 13 secs from the left eye of a normal 4-year-old spayed female Beagle dog with a brown iris. Images were obtained utilizing the narrowband filter combinations, tailored to each angiographic dye.

**Figure 3:** Representative posterior segment sodium fluorescein (A) and MB-102 angiography (B) images obtained from the right eye of a normal 4-year-old spayed female Beagle dog. Images were obtained utilizing the narrowband filter combinations, tailored to each angiographic dye.

**Figure 4:** Posterior segment angiography images obtained following injection of MB-102 in a 4-year-old (A) and a 5-year-old male Beagle dog (B). Image depict use of the broadband (A) and narrowband (B) filter combination.

**Figure 5:** Posterior segment SF (A) and MB-102 (B) angiography images obtained from the right eye of a 1-year-old female Mixed breed dog with retinal disease. Images illustrated the presence of two window defects (arrows), which appear more using MB-102 due to reduced background fluorescence and improved image contrast.

## Figures

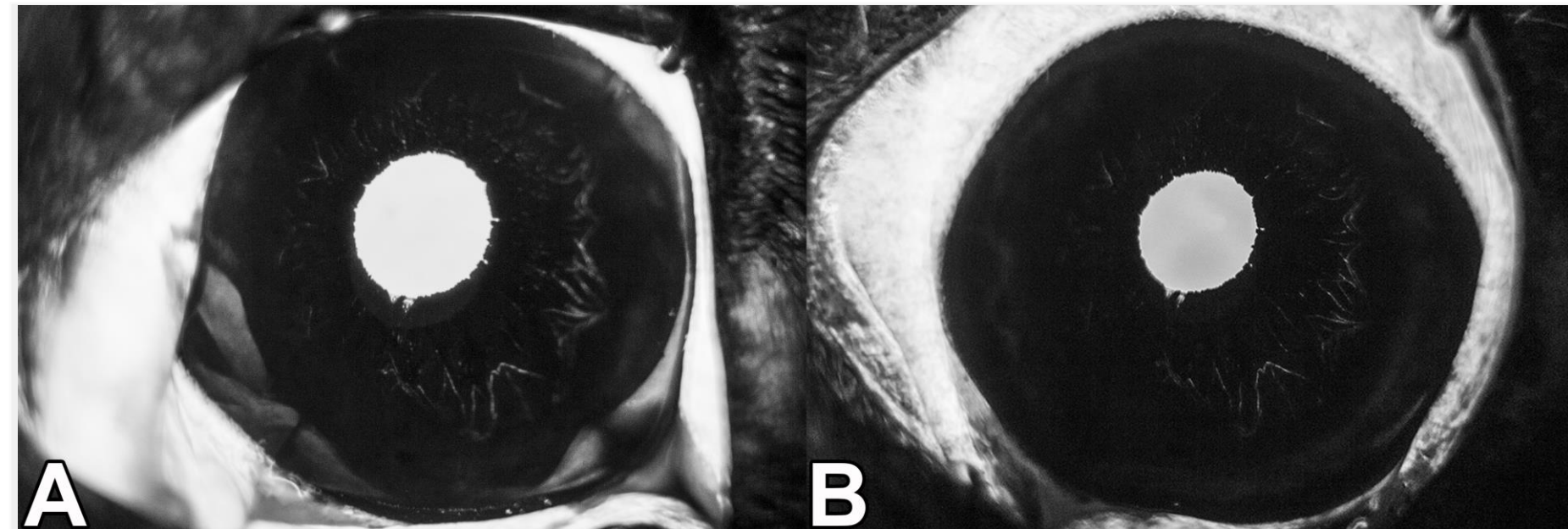


Figure 2

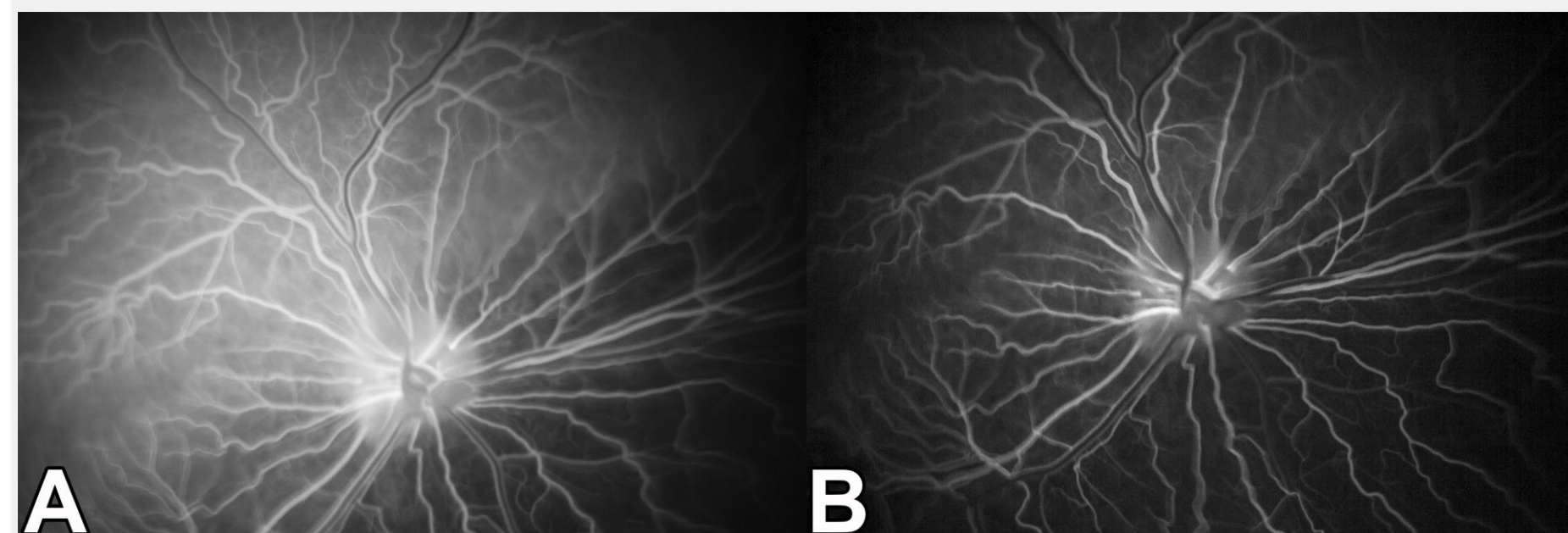


Figure 3

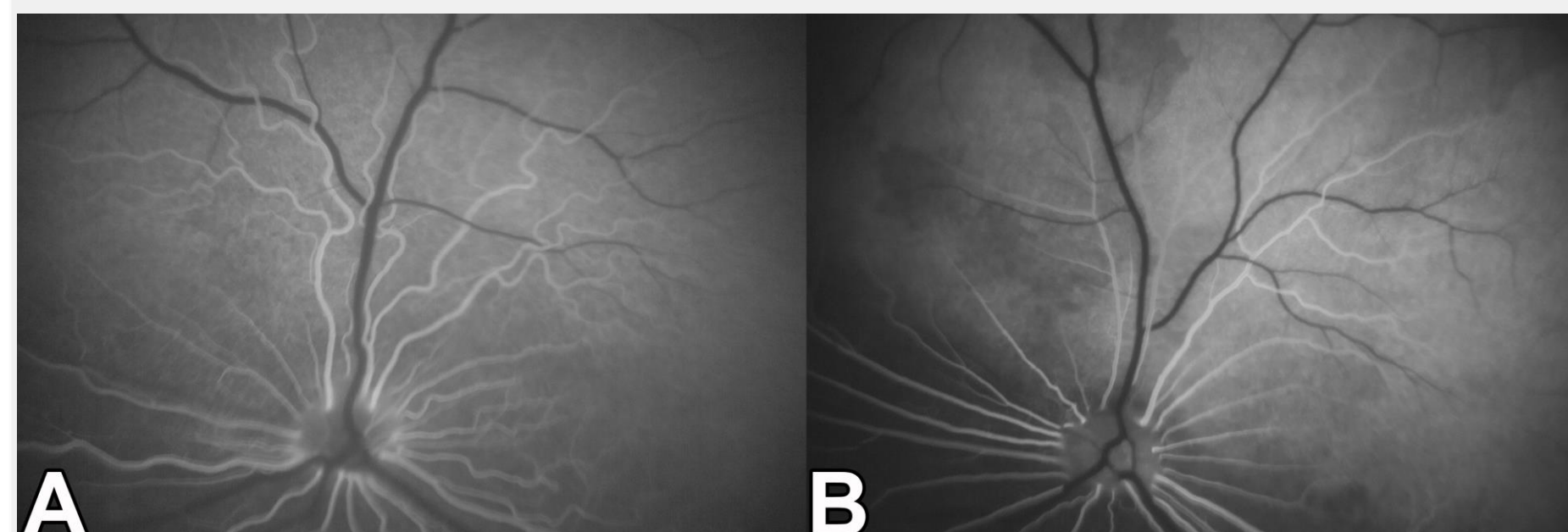


Figure 4

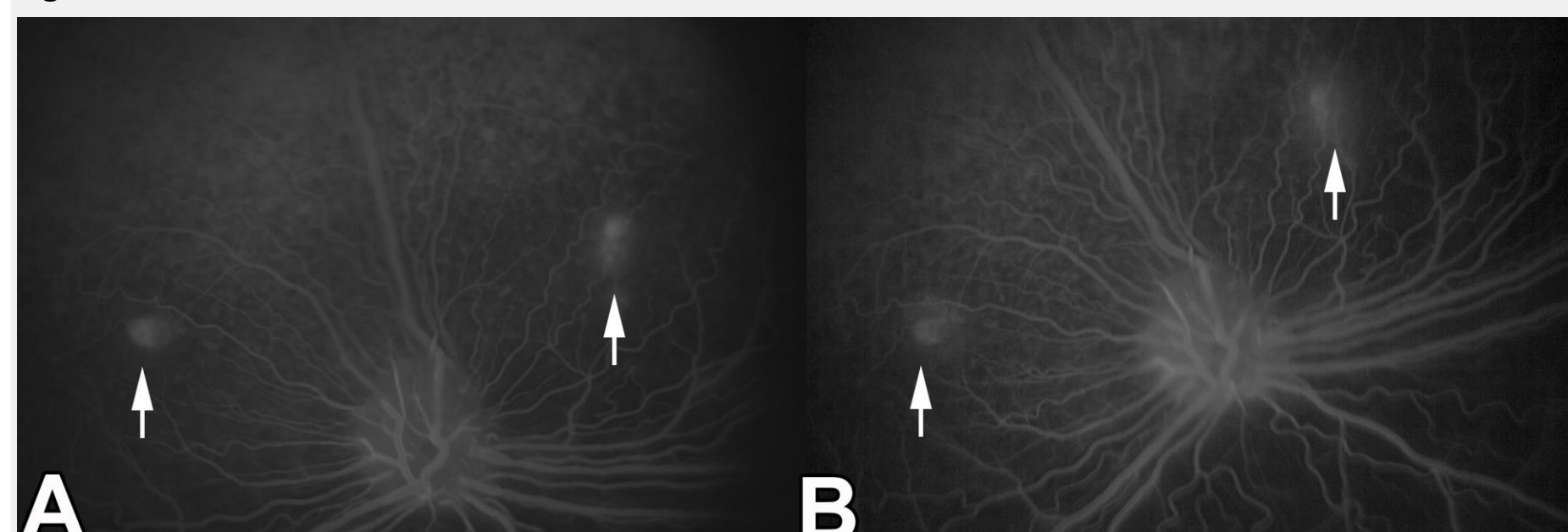


Figure 5

## Results

Representative images, depicting various phases during anterior (Figure 2) and posterior (Figure 3) segment angiography are depicted. All phases and phase intervals during both anterior and posterior segment angiography were identified, regardless of the agent employed. However, fluorescence and visualization of the iridal blood vessels was hindered in some dogs, irrespective of the agent employed, due to the degree of iridal pigmentation present. Use of the narrowband filter set (for both dyes) provided superior image quality and contrast, as compared to the broadband filter set (Figure 4). Slight improvement in image contrast was observed using MB-102 in the later time periods, due to a reduction of vessel wall staining in both normal and diseased eyes. Additionally, observation of pathologic change (i.e. window defects) appeared more obvious with use of MB-102 due to reduced background fluorescence (Figure 5). Dye extravasation in the late time periods was common and considered comparable between agents.

No statistically significant difference was noted between the two fluorescent agents for any phase or phase interval during anterior and posterior segment angiography. (Tables 1 and 2)

No adverse effects were identified following IV administration of SF or MB-102. Staining of the skin was observed shortly following administration of SF, as well as discoloration of the urine up to 24 hours post-injection. No skin or urine discoloration was observed with administration of MB-102.

## Conclusion

MB-102 is in on-going clinical studies for measurement of glomerular filtration rate at the point-of-care. No serious adverse events have been seen to date in these human studies. Based on the results of current study, MB-102 appears to also be a viable fluorescent tracer agent for conducting ocular angiography in dogs. Due to its unique spectral and metabolic characteristics (increased half-life), and its expected safety profile, MB-102 should allow an expansion in how ocular angiography may be employed to diagnose and monitor a variety of ophthalmic diseases.

	Anterior segment			
	Sodium fluorescein		MB-102	
	Normal	Diseased	Normal	Diseased
Onset of fluorescence (pupil)	9.3 (6.3-10.3)	9.7 (5.6-14.0)	8.0 (6.0-10.0)	9.6 (5.0-14.3)
Arterial phase	12.0 (10.6-15.0)	-	12.2 (8.0-13.6)	-
Arterial phase interval	1.2 (1.0-1.7)	-	1.2 (1.0-2.7)	-
Capillary phase	13.3 (11.6-16.6)	-	13.3 9.6-16.0)	-
Capillary phase interval	1.0 (1.0)	-	1.0 (1.0-1.3)	-
Venous phase	14.3 (12.6-17.6)	-	14.3 (10.6-17.0)	-
Extravasation – aqueous humor (minutes)	2.5 (1.0-3.0)	2.0 (1.0-10.0)	2.0 (1.0-4.0)	2.0 (1.0-10.0)

Table 1: Median (range) time (in seconds) to phases and phase intervals after IV injection of SF and MB-102 for anterior segment angiography.

	Posterior segment			
	Sodium fluorescein		MB-102	
	Normal	Diseased	Normal	Diseased
Arterial phase	7.3 (5.3-8.6)	6.5 (2.6-9.6)	6.2 (5.6-8.6)	6.5 (3.3-12.0)
Arterial phase interval	2.3 (2.0-4.3)	2.4 (1.4-2.7)	2.7 (1.3-4.6)	2.0 (1.3-3.0)
Arterio-venous phase	9.5 (8.6-12.3)	8.5 (5.0-12.3)	9.5 (7.3-12.6)	8.3 (4.6-15.0)
Arterio-venous phase interval	2.0 (1.7-5.3)	1.7 (1.3-7.7)	2.4 (1.3-4.4)	2.2 (1.7-6.0)
Early venous phase	11.3 (11.0-17.6)	10.5 (7.0-20.0)	11.5 (9.6-16.6)	10.3 (6.6-21.0)
Early venous phase interval	5.2 (3.7-6.0)	4.6 (3.0-9.0)	5.6 (4.3-7.3)	4.7 (3.0-9.0)
Late venous phase	16.7 (15.3-23.0)	13.8 (12.3-29.0)	16.2 (14.3-23.6)	15.2 (13.0-30.0)

Table 2: Median (range) time (in seconds) to phases and phase intervals after IV injection of SF and MB-102 for posterior segment angiography.